



Balanitis Xerotica Obliterans, the Topical Application of Tacrolimus Ointment, and the Result: An Institutional Study

Anowar Ali Mallick, Tapas Kumar Majhi, Supriya Basu, Dilip Kumar Pal

Submitted November 24, 2012 - Accepted for Publication February 4, 2013

ABSTRACT

Background: Balanitis xerotica obliterans (BXO) is a well-known chronic disease affecting male genitalia. There are several treatment options available for this. This study was performed to establish the efficacy of tacrolimus ointment as a mode of nonsurgical management of early BXO changes.

Introduction: BXO is a chronic, lymphocyte-mediated skin disease causing glandular urethral stricture of unknown origin. Exact incidence of the disease is obscure; there are several surgical and nonsurgical treatment options available. Among the nonsurgical management, the use of tacrolimus (immunomodulator) ointment is being considered.

Methodology: This study was performed at our institution among the patients attending the outpatient department with typical clinical features of BXO during the year 2011. Thirty cases were studied.

Results and Discussion: The majority (63.33%) of cases presented during the third to sixth decade of life. Symptomatic relief occurred in 16 cases (53.33%) treated with tacrolimus ointment. There are several modes of nonsurgical management, including steroid ointment usage, carbon dioxide laser therapy, topical tacrolimus application, etc. Among these therapies, the use of topical tacrolimus has promising results with better symptomatic relief and fewer side effects, as seen in our study.

INTRODUCTION

Balanitis xerotica obliterans (BXO) was first described by Stuhmer in 1928 in Munster, Germany [1,2]. BXO is the other name of the disease Lichen sclerosus et atrophicus (LSA). It is basically the male genital form of LSA and is the most common chronic, lymphocyte-mediated skin disease causing glandular urethral stricture [1-4] of unknown origin. BXO is a rare disease that affects only 6 of 1000 males (0.06%) [5,6]. It can affect males of any age, especially in the third to fifth decade of life [7]. The traditional treatment has been radical circumcision when the disease is affecting the penile skin and at a young age [7]. However, many conservative treatment options are now available [6]. True incidence is obscure, but it is more common in the white population and has been reported as uncommon in other ethnicities [8].

The exact etiology is unknown. Chronic infection with borrelia burgdorferi [9] has been proposed, and other researchers showed it to be autoimmune in etiology [7]. On medical management of the disease, long-term antibiotic therapy or topical corticosteroid or immunomodulator therapy have been proposed. Tacrolimus is an immunomodulator currently used systemically in transplant medicine and has been recently licensed for treating atopic dermatitis. Topical therapy with tacrolimus in cases of BXO has been reported with varying efficacy [10,11].

This study was performed to assess the efficacy of the topical application of tacrolimus as a non-surgical modality of treatment in early BXO involving the meatus and fossa navicularis, and relapsed cases of meatal stenosis after surgical procedures.

KEYWORDS: Balanitis xerotica obliterans (BXO), topical, tacrolimus, treatment

CORRESPONDENCE: Dilip Kumar Pal, MS, MCh, Vinayak Garden, Flat No. A/3D 41B, Simla Road, Kolkata, India 700006 (drdkpal@yahoo.co.in)

CITATION: *UroToday Int J.* 2013 April;6(2):art 14. <http://dx.doi.org/10.3834/uij.1944-5784.2013.04.01>

Table 1. Agewise distribution of cases.

Age Group Affected	No. of Patients	% of Distribution
10 - 20 years	5	16.67%
21 - 30 years	6	20%
31 - 40 years	7	23.33%
41 - 50 years	4	13.33%
51 - 60 years	2	6.67%
61 years and up	6	20%

MATERIALS AND METHODS

After approval from the institutional ethical committee, the present study was performed in Bankura Sammilani Medical College for a period of 1 year (January 2011 to December 2011), and 30 cases have been included in this study. All the patients attending in our outpatient department with typical clinical features of BXO have been included in the study; a detailed history was taken, patients underwent some tests (uroflowmetry, basic blood investigations, and urinalysis), and patients were treated with topical tacrolimus for a period of 6 weeks. Patients aged more than 75 years were excluded from the study. All the patients gave consent to be included in the study. The statistical tests were performed using IBM SPSS® Statistics 20 software.

RESULT AND ANALYSIS

Among the study population of thirty patients, 5 patients were bellow 20years of age, 6 patients were above 60 years of age and rest 19 patients (63.33%) were in the age group 30 to 59 years. Youngest boy in this study was 14 years old and oldest was 71 years old (Table 1). All patients were male. All had sufficient urinary obstructive symptoms such as straining, the splaying of their urinary stream, prolonged voiding time, and had glans and meatal appearances highly suggestive of BXO (Figure 1). Eighteen of them had a history of minimal surgical treatment with meatal dilatation or meatotomy and a topical application of the steroid-like clobetasol or mometasone, but none of them had long-term relief of symptoms so they frequently visited the outpatient department and needed dilatation without effective symptom relief.

Two middle-aged (39 years and 44 years) men had buccal mucosal urethroplasty for long, segmented anterior urethral strictures; 2 years after the surgery they developed meatal stenosis and demonstrated persisting BXO symptoms during

Figure 1. A clinical presentation of BXO changes seen at different stages of treatment in 2 different patients; a,b) the appearance of the glans and external urethral meatus at presentation; c,d) the appearance of the same after an application of tacrolimus ointment for 6 weeks.

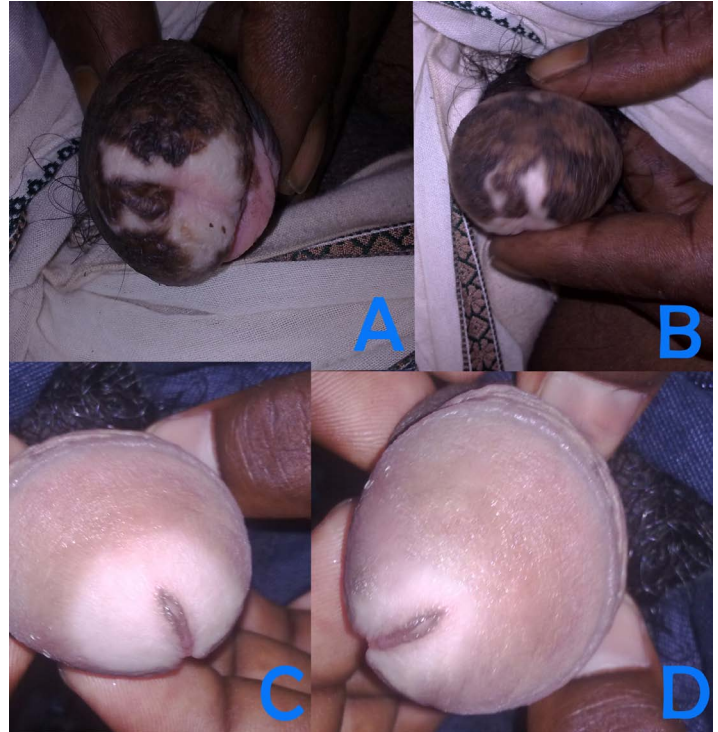


Figure 2. Uroflometry graphs of 2 patients; above – before treatment, below – after treatment.

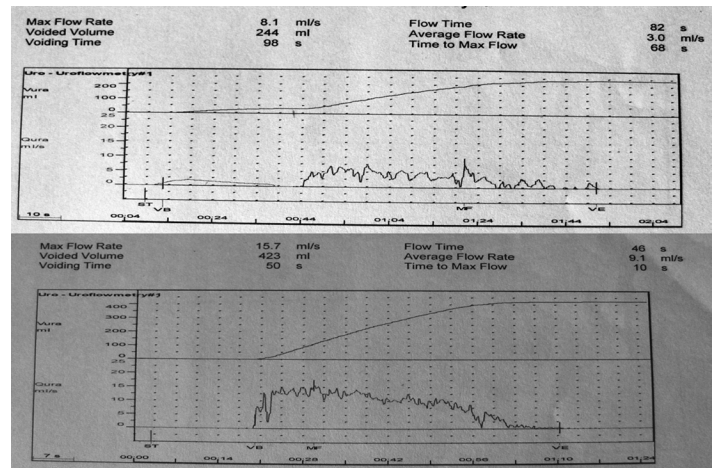


Figure 3. Histopathological characteristics of BXO changes: (original magnification X100, H/E Stain) hyperkeratosis, an absence of rete ridges, a pale upper dermis, band-like lymphocytes infiltrating to the dermis, and cleft-like space separating the epidermis from dermis.

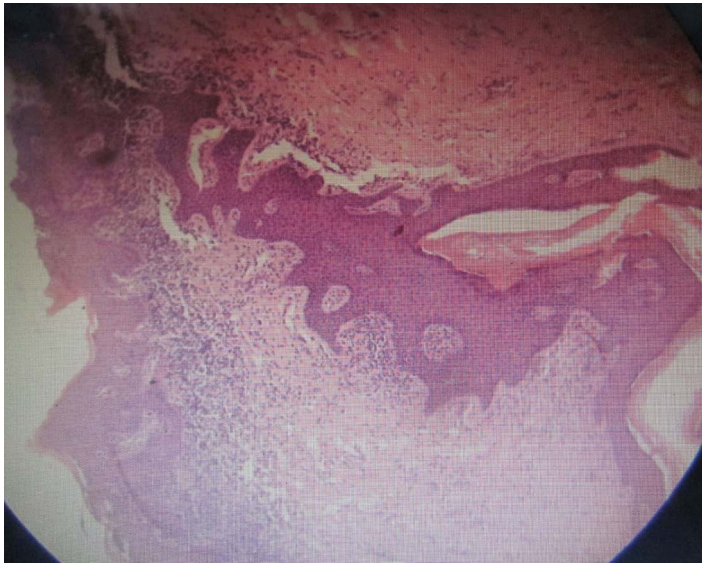


Table 2. Observed histopathological changes.

No. of Cases	Histopathological Report
9	early BXO changes
20	BXO changes
1	Zoon balanitis

this period of study.

Uroflowmetry was performed in all cases except the case with suprapubic cystostomy, and the average flow was less than 4 ml per second in most cases (24 cases, 80%) before the application of tacrolimus ointment (Figure 2). Retrograde urethrography and urethroscopy were performed routinely to assess the length of urethral involvement. Long segment strictures were excluded from this study. A glans biopsy was done in all cases. Nine cases had early lichenoid reactions suggestive of early BXO, 20 cases had fully developed BXO (histopathological changes) (Figure 3), and 1 case where the clinical appearance was BXO with obstructing urinary symptoms, but the histopathological report came to be Zoon balanitis (Table 2).

All patients were treated with a local application of 0.03% tacrolimus twice daily for 3 weeks and then 0.1% tacrolimus for the next 3 weeks. The dosage schedule is controversial as there are not enough studies yet to determine the exact dosage, which depends on a) the few earlier studies, b) the availability of the ointment in these strengths, and c) a higher dose that may cause allergic reactions as stated by the manufacturer. In this study, the previously mentioned dosage was used. All

patients tolerated the drug well, except for the complaint of a transient burning sensation at that site and pruritus in 6 cases. There were no other side effects noted during this study period.

Symptomatic relief of symptoms occurred in 53.33% (16 cases) of the total population studied, evidenced by the subjective improvement of urinary flow and the reduced frequency of urethral dilatation compared to earlier tests. These were supported by objective studies as well. Seventeen cases (56.67%) showed improved maximum flow rate at uroflowmetry (Qmax), and an average flow rate at uroflowmetry (Qavg) after the application of tacrolimus ointment at a 2-month follow-up during the study period (Figure 2). In 1 patient, there was objective improvement in urine flow but no subjective symptomatic relief. The cause may have been psychological, resulting from prolonged suffering with the disease. This improvement in uroflowmetry was statistically significant also (a Wilcoxon signed-rank test was performed on the uroflowmetry values before the start of therapy and at the end of therapy at a 6-week follow-up visit; the *P* value calculated was 0.002).

The appearance of the glans after the application of tacrolimus was better (16 cases, 53.33%) and less dry (Figure 1). However, histopathological changes after the use of tacrolimus were not confirmed via biopsy. Patients with early BXO changes responded more. The patient with suprapubic cystostomy with a narrow and rigid meatus, which was difficult to dilate, became pliable and amenable to dilatation. Suprapubic cystostomy catheter was removed after 1 month and the patient started voiding with a narrow stream.

It was also noted that the patient with Zoon balanitis did respond to the tacrolimus therapy; at presentation, the Qmax and Qavg were 13 and 7.3 ml a second, respectively, and at the end of therapy at a 2-month visit, those values became 22 and 11.5 ml a second, respectively.



DISCUSSION

BXO is a chronic, debilitating, and inflammatory condition that impairs urinary flow, affects sexual function, and alters the aesthetic appearance of the glans, affecting the psychosocial status of patient. It is a chronic inflammatory disease of the skin of unknown etiology [7]. It is the male variant of lichen sclerosus et atrophicus [3,7,12]. The name BXO was derived from 3 components of the disease, which are balanitis (chronic inflammation of the glans), xerotica (abnormally dry appearance of the lesion), and obliterans (the association of occasional endarteritis) [7]. The exact etiology is unknown. Different causes have been postulated, including infection by spirochetes, autoimmune disease, a genetic predisposition (human leukocyte antigen, HLA association), reactive oxidative stress, or some carcinogenic process [7,12].

It has no racial predisposition. It can affect any age group but is more prevalent in the third to fifth decade of life [2,5,7], as seen in our study. It is usually asymptomatic in the early course of the disease, and physical changes occur over months or years and may include color or textural changes at the prepuce skin and the glans only [12,13]. Symptoms are more dominant in uncircumcised men. They range from pruritus, a burning sensation at the glans, hypoesthesia, a painful erection, recurrent features of urinary tract infection, a decrease in urinary flow, features of urethritis, phimosis and paraphimosis, and squamous cell carcinoma may develop at the area of involvement [7,13]. There may be extragenital features such as lichen sclerosis affecting other parts of the body. Usually the area affected looks like a whitish patch, the superficial skin is thickened, and it is dry [10]. Though the typical clinical appearance is enough to diagnose the case, other differential diagnoses must be ruled out, such as venereal diseases by serological tests. It may be confirmed by histopathological examination. In some studies, it has proved to be a precancerous lesion leading to carcinoma of the penis on a long-term basis [7]. Histologically, BXO is characterized by hyperkeratosis, epidermal atrophy, vascular alteration of basal keratinocytes, subepidermal edema, sclerosis of the subepidermal collagen, and lymphocytic infiltration [1,8,12].

Early treatment is necessary to delay or prevent the long-term complications of the disease. For this, several medical managements are used, such as topical or intralesional steroid usage, topical steroids with skin stretching, topical tacrolimus, and carbon dioxide laser treatments [12,14-16]. Windahl et al.[17] has shown encouraging results in his study after the application of carbon dioxide laser therapy (CO₂ settings: output = 15 to 20 watts, in defocus mode; wavelength = 10000

nanometers) for BXO changes for an average of 30 months both in terms of cosmetic and functional improvement. But they did not clearly mention objective outcomes and the timing of CO₂ laser therapy [18]. CO₂ lasers cause heat vaporization of cells, thus causing the death of BXO cells. However, we don't have any experience with CO₂ laser therapy in this study. Different types of surgical procedures may be done in advanced cases.

Kiss [14] and Ebert et al. [19] questioned the use of topical steroids as they may cause epithelial atrophy and its side effects. Tacrolimus is an immunomodulator and works by inhibiting the production of interleukin 2 and subsequent T-cell activation. This reduces or delays the process of balanitis and heals BXO [12,14,20]. The topical application of tacrolimus (0.03 to 0.1%) appears promising in early lesions, as seen in this study by the symptomatic relief and increase in urinary flow rates. The need for dilatation had also decreased. However, further studies, preferably with a control arm, are needed to know the exact dosage schedule, adverse effects, contraindications, etc., of topical tacrolimus usage in early BXO changes, and usage after circumcision and urethroplasty in cases of BXO diseases.

REFERENCES

1. Meffert, J. J., B. M. Davis, et al. (1995). "Lichen sclerosus." *J Am Acad Dermatol* 32(3): 393-416; quiz 417-398. [PubMed](#)
2. Stühmer, A. (1928). "Balanitis xerotica obiterans und ihre Beziehungen zur 'Kraurosis glandi et praeputii penis.'" *Arch Dermatol Syph* (Berlin) 156: 613.
3. Finkbeiner, A. E. (2003). "Balanitis xerotica obliterans: a form of lichen sclerosus." *South Med J* 96(1): 7-8. [PubMed](#) | [CrossRef](#)
4. Laymon, C. W. and C. Freeman. (1944). "Relationship of Balanitis xerotica obliterans to lichen sclerosus et atrophicus." *Arch Derm Syph* 49: 57-59. [CrossRef](#)
5. Meuli, M., J. Briner, et al. (1994). "Lichen sclerosus et atrophicus causing phimosis in boys: a prospective study with 5-year followup after complete circumcision." *J Urol* 152(3): 987-989. [PubMed](#)
6. Parsad, D. and R. Saini (1998). "Oral stanozolol in lichen sclerosus et atrophicus." *J Am Acad Dermatol* 38(2 Pt 1): 278-279. [PubMed](#) | [CrossRef](#)
7. Jordan, G. H. and K. A. McCammon. (2011). "Surgery of the Penis and Urethra." *Campbell-Walsh Urology*, 10th ed. WB Saunders; Philadelphia, PA: 961-962.



8. Thomas, R. H. M., C. M. Ridley, et al. (1983). "The association of lichen sclerosus et atrophicus and autoimmune related disease in male." *Br J Dermatol* 109: 661. [CrossRef](#)
9. Shelley, W. B., E. D. Shelley, et al. (1999). "Long-term antibiotic therapy for balanitis xerotica obliterans." *J Am Acad Dermatol* 40(1): 69-72. [PubMed](#) | [CrossRef](#)
10. Depasquale, I., A. J. Park, et al. (2000). "The treatment of balanitis xerotica obliterans." *BJU Int* 86(4): 459-465. [PubMed](#)
11. Pandher, B. S., M. H. Rustin, et al. (2003). "Treatment of balanitis xerotica obliterans with topical tacrolimus." *J Urol* 170(3): 923. [PubMed](#) | [CrossRef](#)
12. Pugliese, J. M., A. F. Morey, et al. (2007). "Lichen sclerosus: review of the literature and current recommendations for management." *J Urol* 178(6): 2268-2276. [PubMed](#) | [CrossRef](#)
13. Scheinfeld, N. S., et al. (2011). "Balanitis Xerotica Obliterans Clinical Presentation." Available at <http://emedicine.medscape.com/article/1074054-clinical>. Updated Aug 2, 2011. Accessed March 21, 2012.
14. Kiss, A. (2006). "The response of clinical balanitis xerotica obliterans to the application of topical steroid-based creams." *J Pediatr Surg* 41(3): 606; author reply 606-607. [PubMed](#) | [CrossRef](#)
15. Ratz, J. L. (1984). "Carbon dioxide laser treatment of balanitis xerotica obliterans." *J Am Acad Dermatol* 10(5 Pt 2): 925-928. [PubMed](#) | [CrossRef](#)
16. Ghysel, C., K. Vander Eeckt, et al. (2009). "Long-term efficiency of skin stretching and a topical corticoid cream application for unretractable foreskin and phimosis in prepubertal boys." *Urol Int* 82(1): 81-88. [PubMed](#) | [CrossRef](#)
17. Windahl, T. and S. Hellsten (1993). "Carbon dioxide laser treatment of lichen sclerosus et atrophicus." *J Urol* 150(3): 868-870. [PubMed](#)
18. Aynaud, O. and F. Plantier (2010). "Genital lichen sclerosus treated by carbon dioxide laser." *Eur J Dermatol* 20(3): 387-388. [PubMed](#) | [CrossRef](#)
19. Ebert, A. K., T. Vogt, et al. (2007). "[Topical therapy of balanitis xerotica obliterans in childhood. Long-term clinical results and an overview]." *Urologe A* 46(12): 1682-1686. [PubMed](#) | [CrossRef](#)
20. Assmann, T. and T. Ruzicka (2002). "New immunosuppressive drugs in dermatology (mycophenolate mofetil, tacrolimus): unapproved uses, dosages, or indications." *Clin Dermatol* 20(5): 505-514. [PubMed](#) | [CrossRef](#)