

Renal Cell Carcinoma with Synchronous Gallbladder Metastasis Treated with Laparoscopic Radical Nephrectomy and Cholecystectomy in the Same Setting

Fausta Ditah, Rajal B. Shah, J. Stuart Wolf Jr.

Departments of Urology and Pathology, University of Michigan Health System

Submitted on 25 June 2008 - Accepted for Publication on 6 October 2008

ABSTRACT

Renal cell carcinoma (RCC) with gallbladder metastasis is a very rare entity, whether as a synchronous or metachronous lesion. Additional ancillary immunohistochemical tests may be required to make the diagnosis. We report the case of a 66-year-old woman with primary RCC and a synchronous gallbladder metastasis, who underwent laparoscopic radical nephrectomy and cholecystectomy in the same setting. Gallbladder histopathology revealed clear cell RCC similar to the primary tumor. With positive immunostaining of the tumor for CA-IX, she responded well to interleukin-2 immunotherapy.

KEYWORDS: Kidney neoplasm, Gallbladder, Metastasis

CORRESPONDENCE: J. Stuart Wolf, Jr., University of Michigan, Department of Urology, 1500 East Medical Center Drive, TC 3875, Ann Arbor, MI, 48109, wolfs@umich.edu

INTRODUCTION

Renal cell carcinoma (RCC) has an unpredictable presentation and a tendency to metastasize to unusual sites. Metastases can be synchronous or can occur metachronously decades after primary diagnosis. Tissue markers, history of RCC, and characteristic histological appearances often aid in the appropriate classification and distinction between primary and secondary organ disease [1]. To date, a few cases have been published in which there has been noted gallbladder disease concurrent with or occurring after primary disease [1-13]. Herein, we report the case of a 66-year-old woman with synchronous primary RCC and gallbladder metastasis at the time of diagnosis.

CASE REPORT

A 66-year-old otherwise healthy woman was incidentally found to have a right renal mass. Computed tomography confirmed an irregular and hypervascular 8-cm mass in the right kidney. There was also a 2-cm hypervascular mass noted in the base of the gallbladder (fig. 1). Combined laparoscopic right radical nephrectomy and cholecystectomy was performed. Renal histopathology revealed high-grade clear cell RCC, pT3aN0,

with peri-nephric fat invasion and no nodal involvement (fig. 2). Histopathology of the gallbladder revealed similar findings, consistent with clear cell carcinoma of renal origin (fig. 3).

With no demonstrable residual disease, close surveillance was elected. Follow-up imaging studies 5 and 8 months after nephrectomy were unremarkable, but imaging 11 months after nephrectomy demonstrated multiple small lung nodules, an exophytic left renal mass, and a left adrenal mass. Since immuno-histochemical stains of the primary tumor had been strongly positive for CA-IX, high-dose interleukin-2 therapy was administered. The patient currently had stable disease 20 months after completion of immunotherapy (32 months after nephrectomy) without additional treatment.

DISCUSSION

Kidney tumors account for about 3% of all adult cancers. RCC accounts for approximately 85-90% of all renal tumors [4-6]. Of patients with RCC, 23-30% present with metastases at the time of diagnosis, most commonly to the lungs, mediastinum, bone, liver, and brain [4]. One of the most notable features of RCC is its metastasis to unusual sites. Metastasis may then

simulate other disease entities, depending on location and organs involved [2,7].

Gallbladder involvement is rare and may be an incidental finding or a symptomatic condition that prompts further investigation. Acute cholecystitis and right upper quadrant pain have been reported with gallbladder involvement [4,6]. On autopsy specimens, gallbladder involvement is rare. The incidence of gallbladder metastasis has been reported to be 0.57% (3 of 523 cases of RCC) in a large autopsy series by Bennington *et al.* [8]. Weiss *et al.* [14] reported 4 cases of gallbladder disease at autopsy in a separate series with 687 cases. Metastatic disease is even rarer during life [8]. In a prior analysis of 20 cases of renal cell carcinoma metastatic to the gallbladder, no significant difference was observed between right and left kidneys or between males and females [1]. Of these 20 cases, 8 occurred more than 3 years after initial nephrectomy. Willis [15] reported that secondary carcinomas hematogenously metastasizing from primary organs to the gallbladder initially generate flat nodules below the mucosa and later grow into pendunculated tumors.

Primary clear cell carcinoma of the gallbladder has also been reported [16]. In some cases, especially in the setting of possible metachronous lesion, it may be difficult to distinguish primary clear cell carcinoma of the gallbladder from metastatic cell disease to the gallbladder from the renal primary. Special stains, such as CA-IX, vimentin, chromogranin A, synaptophysin, PAS,

CD10, CEA, and CA19-9, can be used to assist in these cases [1,9,10].

Most patients with clinically localized renal tumors are cured by surgical resection. In the setting of metastatic disease, patients should be clinically evaluated for metastatectomy and systemic therapy. Immunotherapy with interferon or interleukin is the most established systemic treatment, but recent advances include the use of targeted (tyrosine kinase) therapy. Our patient received interleukin-2 and had a stable tumor burden 20 months after treatment. Regarding her prognosis, multiple organ metastatic disease, as she has, correlates with a worse outcome [6]. However, Hellenthal *et al.*

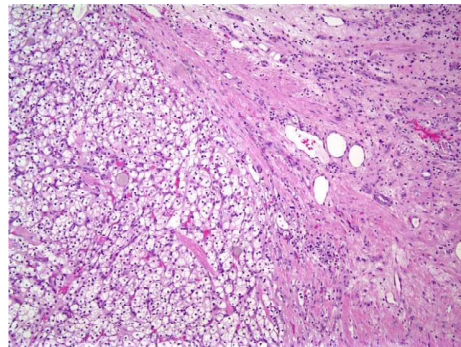


Figure 2. 10x Hematoxylin-eosin stain of resected kidney mass. Left half of the field illustrates conventional clear cell type renal cell carcinoma demonstrated by organoid growth pattern and acini lined by clear cells.

doi: 10.3834/uij.1939-4810.2008.11.04.f2

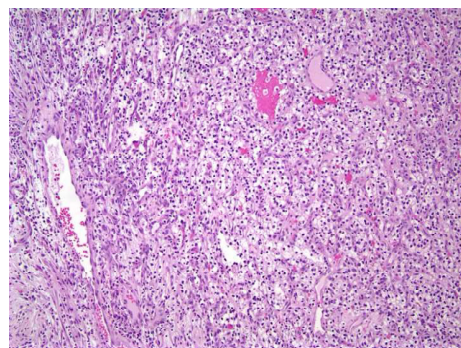


Figure 3. 10x Hematoxylin-eosin stain of gallbladder resection demonstrates tumor composed of clear cells with organoid vascular growth pattern, identical to primary tumor.

doi: 10.3834/uij.1939-4810.2008.11.04.f3

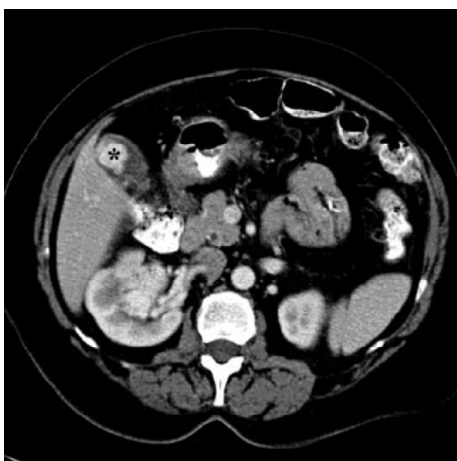

Figure 1. CT of primary RCC with gallbladder metastasis. There is a right renal tumor and associated mass in the gallbladder (black asterisk). Both lesions demonstrate similar hypervascular enhancement.

doi: 10.3834/uij.1939-4810.2008.11.04.f1

[17] recently reported a case similar to ours, with simultaneous nephrectomy and cholecystectomy for concurrent RCC in the kidney and gallbladder, with 30-month disease-free survival without systemic therapy. Our patient's constellation of disease, already unusual with the synchronous gallbladder metastasis, is even more notable when considering her contralateral renal metastasis; bilateral RCC has an incidence of only 1.8% [2].

In conclusion, renal cell carcinoma metastatic to the gallbladder is unusual. The majority of such patients are asymptomatic. Management should be undertaken in the context of the patient's condition and with systemic therapy considerations.

REFERENCES

- [1] Aoki T, Inoue K, Tsuchida A, Aoki T, Kasuya K, Kitamura K, Koyanagi Y, Shimizu T. Gallbladder metastasis of renal cell carcinoma: report of two cases. *Surg Today*. 2002;32(1):89-92.
- [2] Fullarton GM, Burgoyne M. Gallbladder and pancreatic metastases from bilateral renal carcinoma presenting with hematemesis and anemia. *Urology*. 1991 Aug;38(2):184-6.
- [3] Ishizawa T, Okuda J, Kawanishi T, Kitagawa T, Yakumaru K, Sekikawa T. Metastatic renal cell carcinoma of the gallbladder. *Asian J Surg*. 2006 Jul;29(3):145-8.
- [4] King DH, Centeno AS, Saldivar VA, Sarosdy MF. Renal cell carcinoma metastatic to the gallbladder or prostate: two case reports. *Urology*. 1995 Nov;46(5):722-5.
- [5] Cohen HT, McGovern FJ. Renal cell carcinoma. *N Engl J Med*. 2005 Dec 8;353(23):2477-90.
- [6] Golbey S, Gerard PS, Frank RG. Metastatic hypernephroma masquerading as acute cholecystitis. *Clin Imaging*. 1991 Oct-Dec;15(4):293-5.
- [7] Finkelstein LH, Coffman LM. Acute cholecystitis or metastatic renal cell carcinoma? a diagnostic dilemma. *J Am Osteopath Assoc*. 1996 May;96(5):314-5.
- [8] Bennington JL, Kradjan RM. *Renal carcinoma*. Philadelphia, PA: WB Saunders; 1997:93.
- [9] Park JS, Chae YS, Hong SJ, Shin DH, Choi JS, Kim BR. Metastatic renal cell carcinoma of the gallbladder. *Yonsei Med J*. 2003 Apr 30;44(2):355-8.
- [10] Bittinger A, Altekruiger I, Barth P. Clear cell carcinoma of the gallbladder. A histological and immunohistochemical study. *Pathol Res Pract*. 1995 Dec;191(12):1259-65; discussion 1266.
- [11] Pagano S, Ruggeri P, Franzoso F, Brusamolino R. Unusual renal cell carcinoma metastasis to the gallbladder. *Urology*. 1995 May;45(5):867-9.
- [12] Brasseur P, Bissen L, Dupont H, Sukkarieh F. [Metastasis to the gallbladder secondary to a clear cell renal tumor]. *J Radiol*. 1999 Jul;80(7):739-40.
- [13] Nojima H, Cho A, Yamamoto H, Nagata M, Takiguchi N, Kainuma O, Souda H, Gunji H, Miyazaki A, Ikeda A, Matsumoto I, Asano T, Ryu M, Nihei N, Maruoka M. Renal cell carcinoma with unusual metastasis to the gallbladder. *J Hepatobiliary Pancreat Surg*. 2008;15(2):209-12. Epub 2008 Apr 6.
- [14] Weiss L, Harlos JP, Torhorst J, Gunthard B, Hartveit F, Svendsen E, Huang WL, Grundmann E, Eder M, Zwirnagl M, et al. Metastatic patterns of renal carcinoma: an analysis of 687 necropsies. *J Cancer Res Clin Oncol*. 1988;114(6):605-12.
- [15] Willis RA. *The spread of tumors in the human body*. London, UK: Butterworth; 1952:218-9.
- [16] Tyson W, Piney A. Hypernephroma of gallbladder. *Br J Surg*. 1926;13(52):757-9. Epub 2005 Dec 9.
- [17] Hellenthal NJ, Stewart GS, Cambio AJ, Delair SM. Renal cell carcinoma metastatic to gallbladder: a survival advantage to simultaneous nephrectomy and cholecystectomy. *Int Urol Nephrol*. 2007;39(2):377-9. Epub 2007 Feb 17.

TO CITE THIS ARTICLE: Ditah F, Shah RB, Wolf JS. Renal Cell Carcinoma with Synchronous Gallbladder Metastasis Treated with Laparoscopic Radical Nephrectomy and Cholecystectomy in the Same Setting. *UIJ*. 2008 Dec;1(5). doi:10.3834/uij.1939-4810.2008.11.04