

Successful En-Bloc Kidney Transplantation from a 7-Month-Old Donor Weighing 14.3 Pounds Into an Adult Recipient: A Case Report

Taqi F. Toufeeq Khan, Suhaib Kamal, Basem Koshaji, Faheem Akhtar

Submitted May 2, 2013 - Accepted for Publication June 16, 2013

ABSTRACT

We report a case of successful transplantation of en-bloc kidneys (EBK) from a 7-month-old male pediatric donor weighing 14.3 pounds into a 94.8-pound, 18-year-old female recipient. The cause of brain death in the infant was pseudomonas meningitis, and the donor and recipient received appropriate intravenous antibiotics. Both ureters were implanted separately and stented. The postoperative course was uneventful except for 2 episodes of acute cellular rejection. She remains well at more than 36 months post-transplantation, with a serum creatinine of 48 $\mu\text{mol/L}$. We recommend en-bloc kidney transplantation into suitable adults if the pediatric donor weighs less than 33 pounds.

INTRODUCTION

The use of small pediatric donor kidneys has been limited due to concerns over technical complications and long-term outcomes [1]. To overcome the shortage of deceased donor kidneys, the transplantation of small pediatric kidneys into suitable adult recipients has become an acceptable option [2,3]. Using both kidneys provides adequate nephron mass for adult recipients, with outcomes similar to standard criteria adult kidneys [3-5]. With refinements in surgical technique and the use of ureteral stents, the vascular and ureteral complications associated with pediatric kidneys have been reduced [6]. To make better use of this limited resource, there are those who advocate adult recipients be given single pediatric kidneys [7]. Even though pediatric kidneys have been reported to have a higher incidence of acute rejection, they have excellent long-term results [8,9]. We report the successful transplantation of en-bloc kidneys (EBK) from a 7-month-old, 14.3-pound donor into an adult recipient.

CASE REPORT

A set of EBK from a 7-month-old donor was allocated to a

panel-reactive, negative-antibodied, 94.8-pound, 18-year-old female transplant candidate with end-stage renal disease secondary to hypertension. The recipient had been on regular hemodialysis for the last 2 years. This 7-month-old infant with Down's syndrome, weighing 14.3 pounds, became a deceased donor secondary to pseudomonas meningitis and was treated with piperacillin/tazobactam. Because of the risk of infection, the recipient was also given a 7-day course of piperacillin/tazobactam. The cytotoxic and flow cytometry cross-matches were both negative, with a 4-antigen mismatch, the only matches being DR4 and A26. This recipient had recently completed a 7-month course of treatment for pulmonary tuberculosis and received rifampicin and isoniazid for 2 months after transplantation.

Both donor kidneys were recovered en bloc with long infrarenal segments of aorta and vena cava (Figure 1a). Superiorly, the aorta was divided at the celiac axis and the vena cava just below the liver to enable a secure suture closure of both these proximal stumps. At the back table, the superior mesenteric artery stump was ligated, followed by closure of both aortic and vena caval stumps with a running 7/0 polypropylene suture, which was negative for leaks. The implantation was extra peritoneal in the right iliac fossa, both

KEYWORDS: 14.3-pound pediatric donor, bacterial meningitis, en-bloc kidneys, kidney transplantation, adult recipient

CORRESPONDENCE: Taqi F. Toufeeq Khan, Section of Kidney Transplantation, Department of Surgery, Riyadh Military Hospital, 11159 Riyadh, Kingdom of Saudi Arabia (taqikahn@yahoo.com)

CITATION: *UroToday Int J.* 2013 August;6(4):art 45. <http://dx.doi.org/10.3834/uij.1944-5784.2013.08.04>

vascular anastomoses were carried out end to side between the distal aorta and vena cava, and the external iliac vessels used running 6/0 polypropylene sutures. Both kidneys perfused very well (Figure 1b). The 2 ureters were implanted separately using the extravesical technique and stented (Figure 2a and Figure 2b). The recipient received anti thymocyte globulin (ATG) and methylprednisolone induction during surgery. Graft function was immediate, with a cold ischemia time of 6 hours 20 minutes and a rewarming time of 37 minutes. Next-day Doppler ultrasound (DUS) and subsequent 99m-Tc nuclear scans confirmed good perfusion and excretion in both kidneys (Figure 3a, Figure 3b, and Figure 4). Since she had recently completed a 7-month course of antituberculous therapy, the ID team recommended that she receive rifampicin and isoniazid for another 8 weeks. The maintenance immunosuppression included tacrolimus, mycophenolate mofetil, and prednisolone, and it was difficult to maintain tacrolimus levels of 8 to 10 µg/L because of rifampicin. She suffered biopsy-proven acute cellular rejection (ACR) in the second and fourth weeks that responded to steroids. Rifampicin was discontinued 8 weeks after transplantation and helped achieve adequate tacrolimus levels. She has remained well since, the kidneys have increased in size to over 8 cm, and serum creatinine 36 months after transplantation was 48 µmol/L.

DISCUSSION

The ever-increasing demand for kidneys has brought about the acceptance of pediatric donor kidneys for use in adults [1,3-5]. Despite earlier concerns with surgical complications [6] and poor outcomes in this age group, recent data suggests that adult candidates receiving en-bloc pediatric kidneys have better long-term results than standard criteria donors [3,4] and may even be equal to live donor kidneys [10]. The registry data from 2003 showed a greater risk of graft loss when single kidneys were used from donors less than 46.3 pounds, and this supported the use of en bloc kidneys rather than single kidneys in donors under the age of 5 or weighing less than 44 pounds. Our donor was 7 months old and weighed only 14.3 pounds, with the kidneys measuring 5 cm. We decided to transplant them en bloc into a suitable adult female recipient who weighed 94.8 pounds. If this donor was a little older and weighed over 33 pounds, we might have considered splitting the kidneys for 2 adults, but with a donor weight of 14.3 pounds, en-bloc implantation was the logical and, in hindsight, correct choice. The recommended practice is to use EBK from donors aged 5 or at a weight of 44.3 pounds. However, Borboruglu reported good results with single kidneys from donors less than 2 years but who weighed more than 30.9 pounds and had a kidney length of 6 cm. Efforts should be made to recover kidneys from small pediatric donors as "en bloc," which have been shown to result in a higher probability of transplantation [4,12]. We were strict in the choice of our recipient and decided on a young female with a low body mass index and a zero-panel reactive

antibody. Knowing that EBK has outcomes similar to living donors, we wanted a young recipient in an attempt to get the best possible longevity match. A female with a low body mass index was chosen so as not to expose the infant kidneys to an excessive creatinine load, and to avoid hyperfiltration by

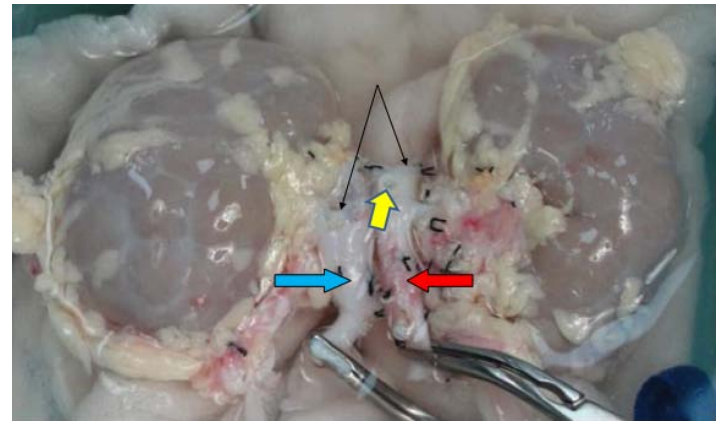
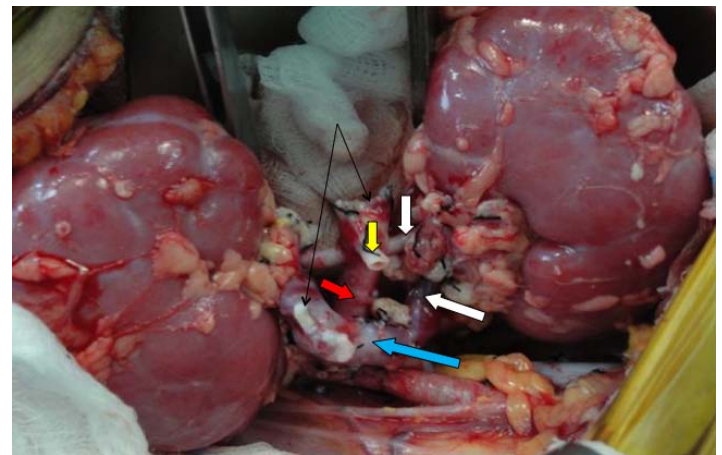


Figure 1b. En-bloc kidneys after reperfusion. Distal ends of aorta and inferior vena cava are anastomosed to the external iliac vessels; long segments of aorta (red arrow), cava (blue arrow), and proximal stumps are visible (black arrows). Both renal arteries and veins (left artery and vein are indicated with white arrows) and ligated SMA stump are also seen (yellow arrow).



CASE REPORT

Figure 2a. Plain abdominal film showing both double-J stents in place; skin clips and the Jackson Pratt drain are also visible.

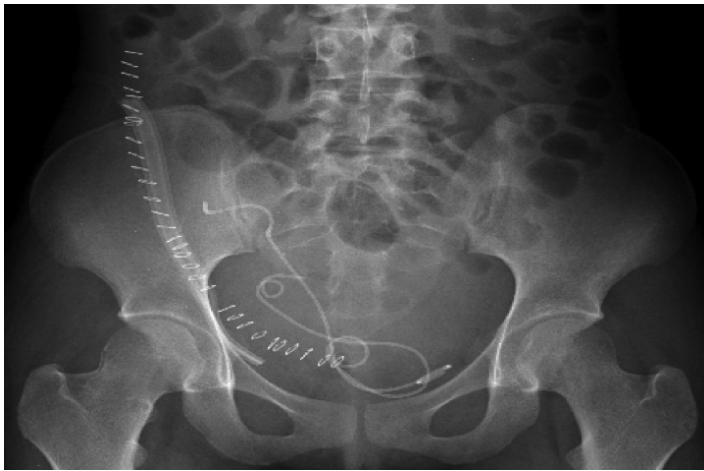


Figure 2b. A double-J stent is seen within a transparent right ureter (white arrow). The left kidney is placed on the bladder (blue star) and the right kidney (black arrow) on the slope of the iliac bone under the oblique muscles. The aorta, a long, right renal artery (yellow arrow) and left renal artery (thin black arrow) are also seen.

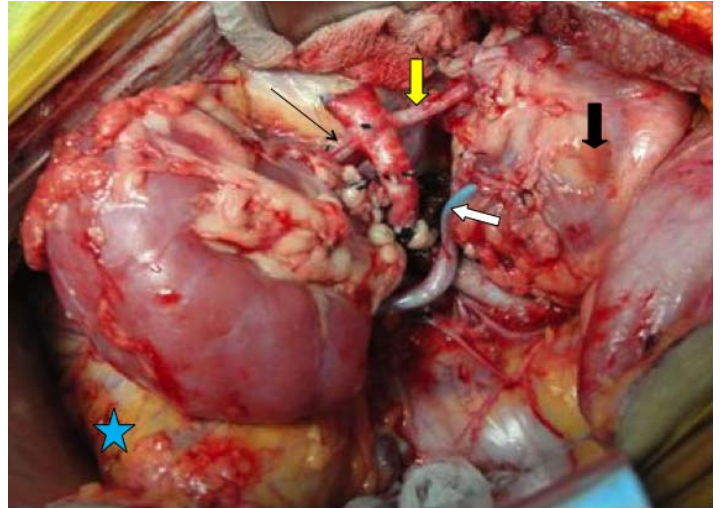
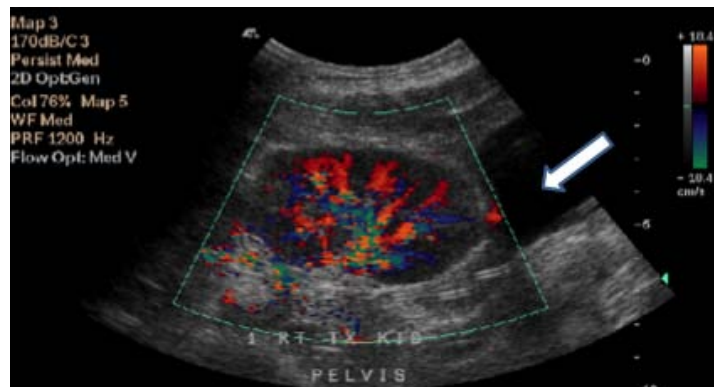


Figure 3a. En-bloc kidneys on ultrasound scan.

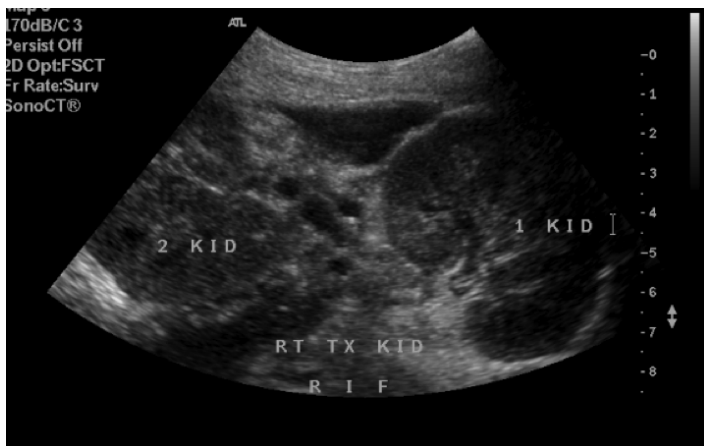

Figure 3b. Well-perfused en-bloc kidneys on DUS. Kidney labeled 1 is laying on the bladder (white arrow).



matching the nephron requirement to the available nephron mass. Technical complications remain a concern, but meticulous attention to detail is important to prevent vascular and ureteric complications. This is especially the case in single pediatric kidneys where the individual vessel size is small and prone to thrombosis, and all ureteroneocystostomies should be stented. Additionally, we paid a lot of attention to the final placement of the EBK to prevent them from twisting or falling over, which could result in thrombosis and graft loss.

The increasing demand for donor kidneys has also resulted in an expansion of the donor pool by broadening the selection

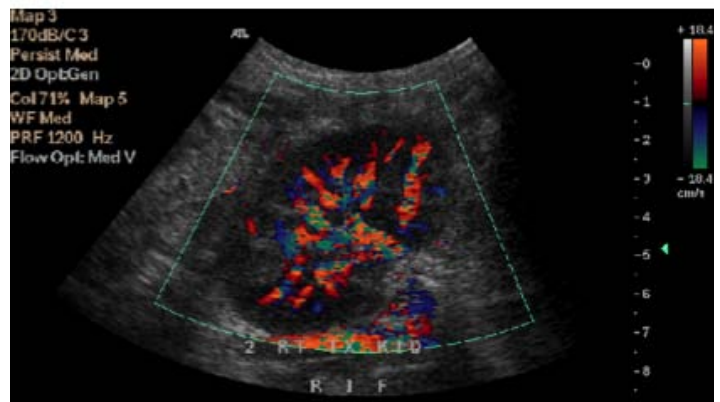
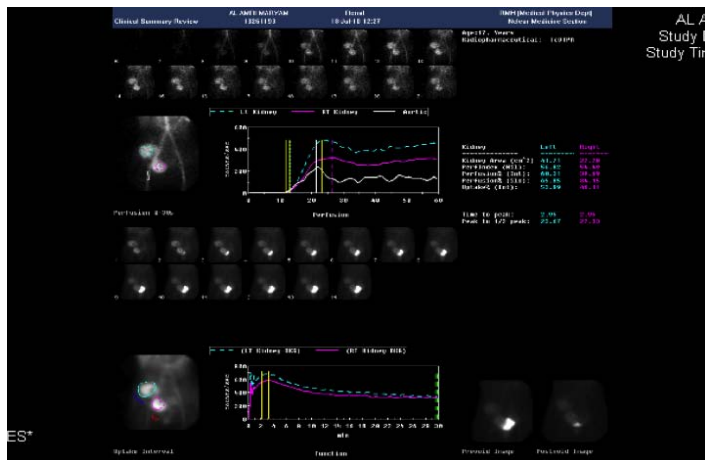


Figure 4. The 99m-Tc nuclear scan showing good perfusion and excretion in both kidneys. One kidney is seen laying on the bladder.



criteria, including the acceptance of organs from donors with bacterial meningitis [13-15]. It has been shown that recipients who received organs from such donors did not develop infectious complications and had results similar to recipients who received organs from uninfected donors if both donor and recipient were given appropriate antibiotics [13-15]. Our experience was similar, both donor and recipient were treated with antibiotics, and the recipient did not develop any infectious complications.

These young kidneys are reported to be prone to ACR because of a higher incidence of delayed graft function and hyperfiltration injury that can upregulate antigen expression [8]. The ACR in our recipient was surprising because 1) she received ATG induction, and 2) graft function was immediate. Despite the higher incidence of ACR, long-term EBK outcomes are similar to the best adult deceased donor [3,4,9]. This may be because of the gradual increase in allograft size and nephron mass, and graft function in our recipient has remained excellent. Both kidneys are now over 8 cm on ultrasound 33 months after transplantation.

We report the successful transplantation of EBK from a 7-month-old pediatric donor weighing 14.3 pounds. There were no surgical or urological complications, and despite 2 early episodes of ACR, the renal function in the recipient has remained excellent. To prevent technical complications and potential graft loss, we recommend EBK transplantation into suitable adults if the pediatric donor weighs less than 33 pounds.

REFERENCES

1. Arrazola, L., H. Sozen, et al. (2000). "Kidney transplant using pediatric donors--effect on long-term graft and patient survival." *Transplant Proc* 32(7): 1839. [PubMed](#) | [CrossRef](#)
2. Mohanka, R., A. Basu, et al. (2008). "Single versus en bloc kidney transplantation from pediatric donors less than or equal to 15 kg." *Transplantation* 86(2): 264-268. [PubMed](#) | [CrossRef](#)
3. Dharnidharka, V. R., G. Stevens, et al. (2005). "En-bloc kidney transplantation in the United states: an analysis of united network of organ sharing (UNOS) data from 1987 to 2003." *Am J Transplant* 5(6): 1513-1517. [PubMed](#) | [CrossRef](#)
4. Pelletier, S. J., M. K. Guidinger, et al. (2006). "Recovery and utilization of deceased donor kidneys from small pediatric donors." *Am J Transplant* 6(7): 1646-1652. [PubMed](#) | [CrossRef](#)
5. Hiramoto, J. S., C. E. Freise, et al. (2002). "Successful long-term outcomes using pediatric en bloc kidneys for transplantation." *Am J Transplant* 2(4): 337-342. [PubMed](#) | [CrossRef](#)
6. Satterwaithe, R., S. Aswad, et al. (1997). "Outcome of enbloc and single kidney transplantation from very young cadaveric donors." *Transplantation* 63: 1405-1410. [CrossRef](#)
7. Balachandran, V. P., M. J. Aull, et al. (2010). "Successful transplantation of single kidneys from pediatric donors weighing less than or equal to 10 kg into standard weight adult recipients." *Transplantation* 90(5): 518-522. [PubMed](#) | [CrossRef](#)
8. Zhang, R., A. Paramesh, et al. (2009). "Long-term outcome of adults who undergo transplantation with single pediatric kidneys: how young is too young?" *Clin J Am Soc Nephrol* 4(9): 1500-1506. [PubMed](#) | [CrossRef](#)
9. Bhayana, S., Y. F. Kuo, et al. (2010). "Pediatric en bloc kidney transplantation to adult recipients: more than suboptimal?" *Transplantation* 90(3): 248-254. [PubMed](#) | [CrossRef](#)
10. Sureshkumar, K. K., C. S. Reddy, et al. (2006). "Superiority of pediatric en bloc renal allografts over living donor kidneys: a long-term functional study." *Transplantation* 82(3): 348-353. [PubMed](#) | [CrossRef](#)

11. Borboroglu, P. G., C. E. Foster, 3rd, et al. (2004). "Solitary renal allografts from pediatric cadaver donors less than 2 years of age transplanted into adult recipients." *Transplantation* 77(5): 698-702. [PubMed](#) | [CrossRef](#)
12. Kayler, L. K., J. Magliocca, et al. (2009). "Recovery factors affecting utilization of small pediatric donor kidneys." *Am J Transplant* 9(1): 210-216. [PubMed](#) | [CrossRef](#)
13. Bahrami, T., H. A. Vohra, et al. (2008). "Intrathoracic organ transplantation from donors with meningitis: a single-center 20-year experience." *Ann Thorac Surg* 86(5): 1554-1556. [PubMed](#) | [CrossRef](#)
14. Lopez-Navidad, A., P. Domingo, et al. (1997). "Successful transplantation of organs retrieved from donors with bacterial meningitis." *Transplantation* 64(2): 365-368. [PubMed](#) | [CrossRef](#)
15. Satoj, S., S. R. Bramhall, et al. (2001). "The use of liver grafts from donors with bacterial meningitis." *Transplantation* 72(6): 1108-1113. [PubMed](#) | [CrossRef](#)